Knee Surgery, Sports Traumatology, Arthroscopy (2022) 30:1132–1137
https://doi.org/10.1007/s00167-021-06499-7

SHOULDER

Limited evidence for biological treatment measures for cartilage and tendon injuries of the shoulder

Lucca Lacheta[1] · **Sepp Braun**[2,3]

Received: 5 November 2020 / Accepted: 8 February 2021 / Published online: 20 February 2021
© European Society of Sports Traumatology, Knee Surgery, Arthroscopy (ESSKA) 2021

Abstract

Purpose To critically review the available literature on the usage of biologics to treat cartilage and tendon injuries of the shoulder.

Methods Four different databases were searched in January 2020 for studies reporting data on bone marrow stimulation, autologous chondrocyte implantation, platelet-rich plasma, autologous concentrated serum, and bone marrow aspirate concentrate for the treatment of cartilage and/or tendon injuries of the shoulder. Prospective, retrospective, cohort and case–control studies as well as case series, systematic reviews and laboratory studies (involving human tissue) were included. Cadaveric or animal studies were excluded. Findings were summarized and an expert opinion on trends was provided.

Results Although there is limited literature available on biologics in cartilage lesions of the shoulder, the advancement from micro- to nanofracture, that is well established for the treatment of cartilage lesions in the knee, may be the next step in the treatment of shoulder lesions as well. The high rate of failure and therefore the complexity of tendon healing following rotator cuff repair has led to a rising interest in biologic augmentation such as platelet-rich plasma and stem cells to enhance tendon-bone-healing and to decrease the prevalence of failure. Despite the increase in publications, there exists a huge heterogeneity of content, quality, and quantity of among studies and their processing methods reporting the use of platelet-rich plasma in rotator cuff repair.

Conclusion Conclusions from individual studies cannot be generalized. Currently, no evidence supports that platelet-rich plasma provides clinical benefits in rotator cuff repair. Similar is reported for microfracture in rotator cuff repair, however, despite no clinical benefits, microfracture has shown to reduce the appearance of structural failures. Although some evidence exists for the use of stem cells form bone marrow aspirate concentrate, results from large case series are still lacking.

Level of evidence Level V.

Keywords Shoulder · Cell therapy · Biological treatment · Tendon injury · Cartilage lesion

Introduction

For many joint injuries, biomechanical aspects such as primary stability of repairs and close to anatomy reconstructive techniques were in the spotlight of researchers over decades. Impressive technical innovations were introduced in minimal invasive shoulder surgery, but tissue healing remains the limiting factor for further increase of clinical and structural results.

The joint's function mainly relies on intact soft tissue structures that allow a well co-ordinated transmission of muscle power and guarantee a precisely centered movement of the joint. As long as the joint is centered, smaller cartilage defects are relatively asymptomatic, as there is no real weight-bearing and forces are evenly distributed. But the natural history of small-sized lesions is to get bigger over time. So even if initially cartilage lesions of the shoulder cause only mild symptoms, it may be relevant to find proper solutions to avoid further increase in size and symptoms and thus decelerate the progress to osteoarthritis. Although

✉ Sepp Braun
s.braun@gelenkpunkt.com

1 Center for Musculosceletal Surgery, Charité Universitaetsmedizin Berlin, Berlin, Germany

2 Gelenkpunkt, Sports and Joint Surgery Innsbruck, Innsbruck, Austria

3 Research Unit for Orthopaedic Sports Medicine and Injury Prevention, Medical Informatics and Technology, University for Health Sciences, Hall, Austria

imaging quality has massively evolved with a wide availability of high-resolution MR, cartilage lesions of the shoulder are often overseen. Compared to the knee, the shoulder's cartilage is very thin both on the humerus and the glenoid, with an uneven thickness pattern. On the glenoid, there is a bare spot in the center of the glenoid and the cartilage thickens to the glenoid rims. At the humeral head the central articulating surface shows thicker cartilage than the peripheral areas. Overall the glenohumeral joint cartilage does not exceed 2 mm thickness [5].

Orthopedic surgeons face traumatic and degenerative pathologies with their different preconditions and treatment standards. In many ways, acute traumatic injuries usually are less critical in terms of healing with conservative or surgical treatment. In contrast, degenerative pathologies, such as most of the rotator cuff lesions still are a challenge for long-term success. If physical therapy did not result in pain-free shoulder function, surgery may be the next step. Rotator cuff repair is the most frequently performed reconstructive shoulder surgery. Surgeons, scientists and engineers have extensively worked on improving all aspects of the procedure to sophisticated minimal invasive arthroscopic repairs even in case of massive tears with the strongest primary fixation and never before achieved compression of the tendon to the footprint. But still non-healing and re-tears of the rotator cuff remain a highly relevant problem. Depending on patient factors and preconditions, retear rates are reported being up to 94% in older studies if the worst comes to the worst [13, 14, 21]. But still the most recent studies frequently report on re-tears rates of 20–30% using the latest surgical techniques [22]. So even if tendon healing became the main focus of research in the last years, there is still debate on what measures can improve healing and reduces re-tear rates in daily practice based on evidence.

This manuscript aims at summarizing the current evidence for cell-based treatment of cartilage and tendon lesions of the shoulder.

Cartilage lesions

Bone marrow stimulation (microfracture)

Bone marrow stimulation—so-called microfracture—has become an established treatment option for cartilage defects of the knee [32, 33]. The principle of bringing bone marrow-derived stem cells to cover a cartilage lesion with fibrocartilaginous tissue has been transferred to the shoulder. As the cartilage is not as thick as in the knee, lesions usually are less contained, making it harder for the blood clot to stay in place. But on the other hand, there is less weightbearing, which should help to achieve reasonable results. Incidental discovery of cartilage lesions is frequent in the glenohumeral joint. Therefore, a single-step procedure is favorable (Fig. 1).

Siebold et al. [31] reported on a small case series of 5 patients suffering from grade IV chondral lesions of the humeral head treated with microfracture and additional periostal flap coverage. All patients reported significant pain relief and improved clinical function at a mean of 25 months postoperatively. Of those, two of 3 patients who underwent a second look arthroscopy presented with a size reduction of the cartilage defect; however, two of 5 patients demonstrated progression of osteoarthritis.

Millett et al. [25] published outcomes of a total of 30 patients who underwent microfracture for symptomatic full-thickness cartilage defects of the glenohumeral joint. 24 out of 30 patients reported significant improvements in patient-reported outcome scores at a mean follow-up of 47 months. Six patients progressed to further surgery. They observed a negative correlation between the size of the cartilage lesion and ASES score, supporting the use of microfracture in small-sized lesions. Furthermore, the greatest improvements were seen in patients who underwent microfracture for isolated lesions of the humerus.

Frank et al. [12] reported of 16 patients (17 shoulders) who underwent arthroscopic microfracture of the humeral head and/or the glenoid surface. After a mean follow-up interval of 28 months, 3 patients went on to subsequent

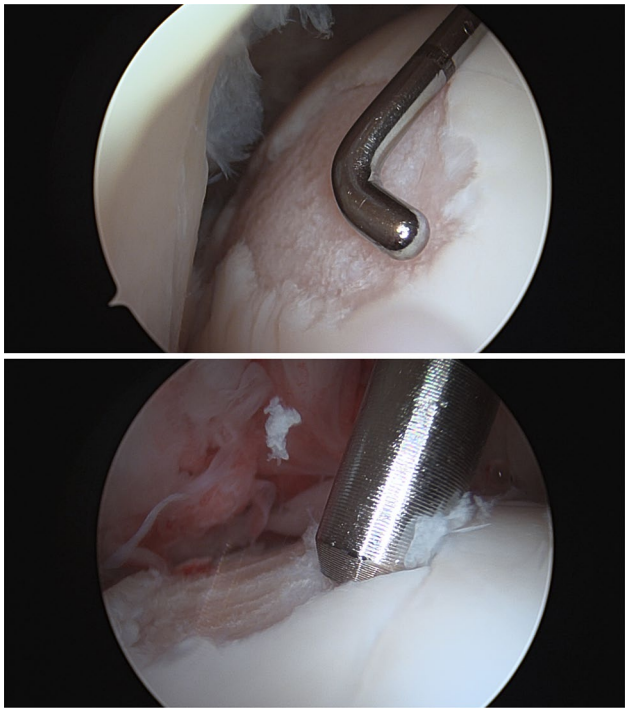

Fig. 1 Chondral lesion of the humerus, before and after debridement. The second image shows the nanofracturing trocar that guides the perforation pin

shoulder surgery (resurfacing or replacement) and were considered to have failed. In the remaining study population, a significant decrease of pain after surgery as well as significant improvements in clinical outcome scores were observed in patients treated for isolated, full-thickness chondral injuries.

Even if there is no literature available for the shoulder, the advancement from micro- to nanofracture, that is well established for the treatment of cartilage lesions in the knee, may be the next step in the treatment of shoulder lesions as well. Nanofracturing means creating perforations with a smaller diameter that go deeper into the bone. This is supposed to reduce the injury to the subchondral plate and increase the amount of bone marrow-derived mesenchymal stem cells at the bone surface.

Autologous chondrocyte implantation (ACI)

Autologous chondrocyte implantation (ACI) constitutes an established procedure in hip and knee surgery to treat medium to large cartilage defects by a two-stage procedure [7, 23, 26]. Transferred to glenohumeral cartilage defects, to date, only the outcome of 13 patients following ACI are reported. Romeo et al. [30] reported a case of an adolescent overhead athlete with a full-thickness cartilage lesion of the humeral head. The patient was treated with open ACI with cultivated chondrocytes harvested from the intercondylar notch of the knee and injected underneath a periosteal patch, harvested from the medial tibia, respectively.

At 12 months postoperatively, the patient gained a full and pain-free range of motion.

Ebert el al. [8] published a case report of a 25-year old patient treated with ACI for a symptomatic, small (10 × 14 mm) cartilage lesion of the glenoid.

Buchmann et al. [4] reported outcomes of 4 patients who underwent ACI for the treatment of large glenohumeral cartilage defects (3 × humeral side, 1 × glenoid side). At a mean follow-up of 41 months the mean visual analog scale for pain (VAS) was 0.3, patients achieved a mean Constant score of 83 points and a mean ASES score of 95 points. In postoperative MRI the defect presented with satisfying coverage with signs of fibrocartilaginous repair tissue according to the authors.

Recently, Boehm and Scheibel [3] reported of 7 patients who underwent ACI for symptomatic focal grade IV cartilage lesions of the humeral head with a median size of 3 cm^3 by an open or arthroscopic approach. After a median follow-up period of 32 months, the subjective shoulder value was 95% compared to 60% preoperatively. Postoperative median Constant score and ASES score were 95–97 points, respectively. Two patients progressed with signs of osteoarthritis and one patient suffered from adhesive capsulitis postoperatively.

In all cases series on ACI, most patients had also concomitant injuries, that were addressed. Thus, it remains somehow unclear how much of the improvement has to be accounted to ACI alone.

Tendon healing

Platelet-rich plasma (PRP)

Many controlled-randomized studies have reported the effects of PRP on partial or complete tears of rotator cuff tendons [18, 27, 29]. These studies delivered heterogeneous results and they have been unable to prove consistency in reduced retear rates and/or improved clinical outcomes [18, 20, 27, 29]. Although meta-analyses on PRP in rotator cuff repair have been published, they were unable to show a clinical benefit [24, 34, 35]. For example, Warth et al. conducted a meta-analysis of Level I and Level II studies and found that among initial tear sizes greater than 3 cm in the anterior–posterior direction, those treated with PRP had a statistically significant reduction in retear rate after double-row repair compared to controls (25.9% vs. 57.1%, $p = 0.046$). Though there was an overall gain in Constant score when PRP was placed at the tendon-bone interface rather than over the surface of the repaired tendon ($p = 0.046$), it should be noted that no statistically significant differences in clinical or structural outcomes between groups treated with and without PRP was found for all included studies, which consisted of tears of all sizes [34]. In another study, Jo et al. conducted a randomized clinical trial with PRP augmentation for large and massive rotator cuff repairs. Among 48 patients at minimum 9 months MRI follow-up, the PRP group had a retear rate of 20%, whereas the retear rate was 55.6% in the control group ($p = 0.023$). However, there was no significant difference in clinical outcomes between the two groups [20]. One randomized controlled trial, performed by Sanchez Marquez et al., showed PRP has no advantage in increasing healing in large and massive tears. Out of 28 total patients with 1-year MRI follow-up, the rate of retear in the PRP group was 71% whereas it was 64% in the control group, with no statistically significant differences found. In addition, no significant differences were found in Constant and DASH scores at 1 year [2]. Whether PRP treatment during arthroscopic rotator cuff repair improves tendon healing rates or patients benefit from improved shoulder function remains unknown.

Recently, Han et al. [15] conducted a meta-analysis in 2019 aiming to investigate the clinical and imaging outcomes of PRP treatment during arthroscopic repair of rotator cuff tears. Thirteen studies on PRP matched their inclusion criteria. Twelve randomized controlled trials with 773 patients reported re-tear rates. Re-tears occurred in 63% (16%) of 392 patients in the PRP group and in 90 (24%) of

381 patients in the control group, which showed a statistically significant difference. While the authors found PRP to have superior postoperative results in Constant score, this difference diminished in ASES score with no significant difference. While the authors conclude that their findings support the use PRP in arthroscopic repair of the rotator cuff, this meta-analysis has to be interpreted with respect to a variety of limitations such as different tear sizes, different methods and processes to produce PRP, and bias associated with meta-analysis.

Autologous concentrated serum

The optimal platelet-rich plasma (PRP) for the treatment of tendon injuries especially rotator cuff lesions has not been determined yet. Cross et al. [6] evaluated the effect of low- versus high-leukocyte concentrated PRP products on catabolic and anabolic mediators of matrix metabolism in diseased rotator cuff tendons. Leukocytes and platelets were significantly more concentrated in high-PRP compared with low-PRP. Increased IL-1β, IL-6 as well as TGFβ-1 and MMP-9 were found in low-PRP. The authors concluded that low-PRP seems to promote normal collagen matrix synthesis and decreases cytokines associated with matrix degradation and inflammation to a greater extent than high-PRP does in moderately degenerative tendons. In severely degenerative tendons neither PRP preparations enhanced matrix synthesis at all.

Stem cells (microfracture, bone marrow aspirate concentration)

Pulatkan and Bilsel [28] investigated the influence of bone marrow stimulation in rotator cuff repair in a retrospective comparative study with a total of 123 patients who were enrolled for full-thickness rotator cuff repair (Fig. 2). 40 patients were treated with a single-row repair, 44 patients with a single-row and microfracture, and 39 patients with a double-row repair. At a minimum follow-up of 2 years the single-row and microfracture group had shown the lowest retear rate (14%) and significantly improved in postoperative Constant score and pain compared to single row alone or double-row repair.

The benefit of bone marrow stimulation in rotator cuff repair with decreased retear rate is supported by Ajrawat and Chahal [1] who performed a meta-analysis to investigate the clinical evidence of the effect of arthroscopic rotator cuff repair, with and without bone marrow stimulation, on rotator cuff healing and functional outcomes. Four studies including 365 patients (Level I randomized trials and Level III retrospective comparative cohort studies) were included. The authors found no statistical difference in DASH score, UCLA score, or the Constant score between repair with bone marrow stimulation and conventional repair. Their pooled analysis of rotator cuff retear rates from 328 patients showed statistically significant difference favoring bone marrow stimulation over conventional repair ($p = 0.002$). In summary, bone marrow stimulation reduced the retear rate after rotator cuff repair but showed no difference in functional outcomes compared to conventional repair, suggesting the use of bone marrow stimulation as a biological and cost-effective approach to improved rotator cuff healing.

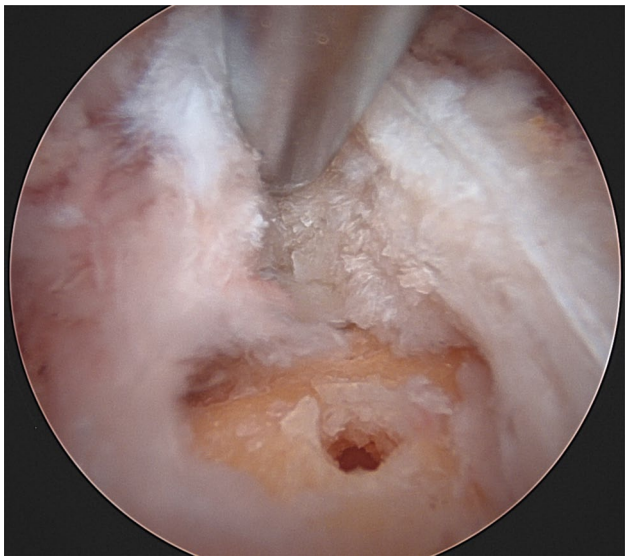

Fig. 2 Microfractured supraspinatus tendon footprint

Another source of stem cells in bone marrow aspirate (BMA) harvested from the iliac crest. The main concern in using BMA to stimulate healing is the low concentration of mesenchymal stem cells found in it. Therefore, various protocols have been developed to concentrate the nucleated cell numbers to produce bone marrow aspiration concentrate (BMAC). The theory is with an increased number of mesenchymal stem cells is to provide an effective environment for healing and regeneration [19].

Fortier et al. [11] compared BMAC to PRP and observed that there are reduced platelets and raised white blood cells in BMAC demonstration that BMAC is acting differently to PRP with likely a different mechanism of action. The concept of BMAC is to improve the recovery of the nucleated cells from the marrow aspirate while decreasing the recovery of non-nucleated cells such as red blood cells. The exact mechanism of BMAC is currently not fully understood [19].

Ellera Gomes [9] investigated the use of BMAC in rotator cuff repair in 14 patients with full-thickness rotator cuff tears in mini-open technique. All patients improved in clinical outcome scores. Postoperative MRI showed that tendon integrity was maintained in all cases at 1 year, but 6 patients (42%) showed high-signal intensity at the critical zone. The

authors concluded that BMAC could be safely implanted as an augment in rotator cuff repair. Hernigou et al. [17] reported the efficiency of BMAC in arthroscopic single-row repair in 45 patients. The primary goal was to compare tendon-to-bone healing to a matched controlled group. The authors found that patients treated with additional BMAC had superior and faster tendon healing when compared to the control group. All shoulders in the BMAC group showed healing after 6 months while only 30 shoulders in the control group showed healing at the same time. Furthermore, at the latest follow-up of 10 years, the integrity of the repair was maintained in 39 patients (87%) in the BMAC group compared to only 20 patients (44%) in the control group. Similar results with improved tendon to bone healing at 10 years postoperatively were presented by Havlas et al. in 2015.[16]

Conclusion

Surgical options for cartilage lesions of the shoulder have not significantly evolved over the last decade [10]. As symptoms are frequently mild in shoulders, clinical tests cannot reliably detect early cartilage lesions and MRI diagnosis is still sometimes difficult, many cartilage defects are incidental findings. Therefore, MACI as a staged surgery is not the first option for the treatment of cartilage defects in the glenohumeral joint. Moreover, the additional expenses, the limited availability in some countries and the moderate clinical results are reasons why ACI has not asserted to be a standard procedure in cartilage defects.

Obviously, a single-step procedure is preferable and microfracture can additionally provide reasonably good clinical results. The evolution of microfracture is nanofracture, perforating the subchondral bone with smaller diameters and deeper into the cancellous bone. This has been shown to improve the results in cartilage treatment in knees and thus may be the next step for the same treatment in glenohumeral joints.

Studies on PRP so far could not show clear clinical and structural benefits with respect to scores and patient satisfaction, but there seems to be evidence for reduced re-tear rates in some of the publications. Unfortunately, the variety of studies on PRP augmentation of rotator cuff repair is high and therefore a clearly positive recommendation cannot be done at present. As healing is particularly challenging in degenerative rotator cuff tears, investigations on the preparation of PRP have suggested that low-leukocyte concentrated PRP (ACI) may be beneficial in promoting the expression of physiologic collagen for tendon to bone healing in moderately degenerative tears. To date, it remains unclear what preparation of PRP could provide the best results.

Bone-Marrow stimulating techniques have shown reduced re-tear rates in multiple studies, but—same as true for PRP—no statistical improvement of clinical scores was shown. Bone marrow aspirate has shown to improve tendon to bone healing and long-term integrity of the repaired tendon. Nonetheless, it is not widely established in clinical daily care, as preparations are heterogenous and elaborate. In contrast, microfracturing of the tendon footprint can be easily incorporated without additional cost in arthroscopic rotator cuff repairs without relevant loss of time. This suggests that microfracture may be added as an additional step in standard rotator cuff repair.

Funding There was no funding of the work.

Compliance with ethical standards

Conflict of interest The authors both have no conflict of interest concerning this paper.

Ethical approval Ethical approval was not necessary as it is a review of the current literature.

References

1. Ajrawat P, Dwyer T, Almasri M, Veillette C, Romeo A, Leroux T et al (2019) Bone marrow stimulation decreases retear rates after primary arthroscopic rotator cuff repair: a systematic review and meta-analysis. J Shoulder Elbow Surg 28:782–791
2. Antuna S, Barco R, Martinez Diez JM, Sanchez Marquez JM (2013) Platelet-rich fibrin in arthroscopic repair of massive rotator cuff tears: a prospective randomized pilot clinical trial. Acta Orthop Belg 79:25–30
3. Boehm E, Minkus M, Scheibel M (2020) Autologous chondrocyte implantation for treatment of focal articular cartilage defects of the humeral head. J Shoulder Elbow Surg 29:2–11
4. Buchmann S, Salzmann GM, Glanzmann MC, Wortler K, Vogt S, Imhoff AB (2012) Early clinical and structural results after autologous chondrocyte transplantation at the glenohumeral joint. J Shoulder Elbow Surg 21:1213–1221
5. Cole BJ, Yanke A, Provencher MT (2007) Nonarthroplasty alternatives for the treatment of glenohumeral arthritis. J Shoulder Elbow Surg 16:S231-240
6. Cross JA, Cole BJ, Spatny KP, Sundman E, Romeo AA, Nicholson GP et al (2015) Leukocyte-reduced platelet-rich plasma normalizes matrix metabolism in torn human rotator cuff tendons. Am J Sports Med 43:2898–2906
7. Ebert JR, Fallon M, Wood DJ, Janes GC (2021) Long-term prospective clinical and magnetic resonance imaging-based evaluation of matrix-induced autologous chondrocyte implantation. Am J Sports Med. https://doi.org/10.1177/03635465209801093635 46520980109
8. Ebert JR, Fallon M, Zheng MH, Tay A (2018) Arthroscopic autologous chondrocyte implantation in the glenohumeral joint: a case report. J Shoulder Elbow Surg 27:e300–e307
9. Ellera Gomes JL, da Silva RC, Silla LM, Abreu MR, Pellanda R (2012) Conventional rotator cuff repair complemented by the aid of mononuclear autologous stem cells. Knee Surg Sports Traumatol Arthrosc 20:373–377

10. Elser F, Braun S, Dewing CB, Millett PJ (2010) Glenohumeral joint preservation: current options for managing articular cartilage lesions in young, active patients. Arthroscopy 26:685–696
11. Fortier LA, Potter HG, Rickey EJ, Schnabel LV, Foo LF, Chong LR et al (2010) Concentrated bone marrow aspirate improves full-thickness cartilage repair compared with microfracture in the equine model. J Bone Jt Surg Am 92:1927–1937
12. Frank RM, Van Thiel GS, Slabaugh MA, Romeo AA, Cole BJ, Verma NN (2010) Clinical outcomes after microfracture of the glenohumeral joint. Am J Sports Med 38:772–781
13. Galatz LM, Ball CM, Teefey SA, Middleton WD, Yamaguchi K (2004) The outcome and repair integrity of completely arthroscopically repaired large and massive rotator cuff tears. J Bone Jt Surg Am 86:219–224
14. Gerber C, Fuchs B, Hodler J (2000) The results of repair of massive tears of the rotator cuff. J Bone Jt Surg Am 82:505–515
15. Han C, Na Y, Zhu Y, Kong L, Eerdun T, Yang X et al (2019) Is platelet-rich plasma an ideal biomaterial for arthroscopic rotator cuff repair? A systematic review and meta-analysis of randomized controlled trials. J Orthop Surg Res 14:183
16. Havlas V, Kotaska J, Konicek P, Trc T, Konradova S, Koci Z et al (2015) Use of cultured human autologous bone marrow stem cells in repair of a rotator cuff tear: preliminary results of a safety study. Acta Chir Orthop Traumatol Cech 82:229–234
17. Hernigou P, Flouzat Lachaniette CH, Delambre J, Zilber S, Duffiet P, Chevallier N et al (2014) Biologic augmentation of rotator cuff repair with mesenchymal stem cells during arthroscopy improves healing and prevents further tears: a case-controlled study. Int Orthop 38:1811–1818
18. Holtby R, Christakis M, Maman E, MacDermid JC, Dwyer T, Athwal GS et al (2016) Impact of platelet-rich plasma on arthroscopic repair of small- to medium-sized rotator cuff tears: a randomized controlled trial. Orthop J Sports Med 4:2325967116665595
19. Imam MA, Holton J, Horriat S, Negida AS, Grubhofer F, Gupta R et al (2017) A systematic review of the concept and clinical applications of bone marrow aspirate concentrate in tendon pathology. SICOT J 3:58
20. Jo CH, Shin JS, Lee YG, Shin WH, Kim H, Lee SY et al (2013) Platelet-rich plasma for arthroscopic repair of large to massive rotator cuff tears: a randomized, single-blind, parallel-group trial. Am J Sports Med 41:2240–2248
21. Jost B, Pfirrmann CW, Gerber C, Switzerland Z (2000) Clinical outcome after structural failure of rotator cuff repairs. J Bone Jt Surg Am 82:304–314
22. Kim KC, Shin HD, Lee WY, Yeon KW, Han SC (2018) Clinical outcomes and repair integrity of arthroscopic rotator cuff repair using suture-bridge technique with or without medial tying: prospective comparative study. J Orthop Surg Res 13:212
23. Krueger DR, Gesslein M, Schuetz M, Perka C, Schroeder JH (2018) Injectable autologous chondrocyte implantation (ACI) in acetabular cartilage defects-three-year results. J Hip Preserv Surg 5:386–392
24. Li X, Xu CP, Hou YL, Song JQ, Cui Z, Yu B (2014) Are platelet concentrates an ideal biomaterial for arthroscopic rotator cuff repair? A meta-analysis of randomized controlled trials. Arthroscopy 30:1483–1490
25. Millett PJ, Huffard BH, Horan MP, Hawkins RJ, Steadman JR (2009) Outcomes of full-thickness articular cartilage injuries of the shoulder treated with microfracture. Arthroscopy 25:856–863
26. Niemeyer P, Laute V, Zinser W, John T, Becher C, Diehl P et al (2020) Safety and efficacy of matrix-associated autologous chondrocyte implantation with spheroid technology is independent of spheroid dose after 4 years. Knee Surg Sports Traumatol Arthrosc 28:1130–1143
27. Pandey V, Bandi A, Madi S, Agarwal L, Acharya KK, Maddukuri S et al (2016) Does application of moderately concentrated platelet-rich plasma improve clinical and structural outcome after arthroscopic repair of medium-sized to large rotator cuff tear? A randomized controlled trial. J Shoulder Elbow Surg 25:1312–1322
28. Pulatkan A, Anwar W, Tokdemir S, Akpinar S, Bilsel K (2019) The clinical and radiologic outcome of microfracture on arthroscopic repair for full-thickness rotator cuff tear. J Shoulder Elbow Surg. https://doi.org/10.1016/j.jse.2019.07.010
29. Randelli P, Arrigoni P, Ragone V, Aliprandi A, Cabitza P (2011) Platelet rich plasma in arthroscopic rotator cuff repair: a prospective RCT study, 2-year follow-up. J Shoulder Elbow Surg 20:518–528
30. Romeo AA, Cole BJ, Mazzocca AD, Fox JA, Freeman KB, Joy E (2002) Autologous chondrocyte repair of an articular defect in the humeral head. Arthroscopy 18:925–929
31. Siebold R, Lichtenberg S, Habermeyer P (2003) Combination of microfracture and periostal-flap for the treatment of focal full thickness articular cartilage lesions of the shoulder: a prospective study. Knee Surg Sports Traumatol Arthrosc 11:183–189
32. Steadman JR, Rodkey WG, Briggs KK (2002) Microfracture to treat full-thickness chondral defects: surgical technique, rehabilitation, and outcomes. J Knee Surg 15:170–176
33. Steadman JR, Rodkey WG, Rodrigo JJ (2001) Microfracture: surgical technique and rehabilitation to treat chondral defects. Clin Orthop Relat Res. https://doi.org/10.1097/00003086-200110001-00033S362-369
34. Warth RJ, Dornan GJ, James EW, Horan MP, Millett PJ (2015) Clinical and structural outcomes after arthroscopic repair of full-thickness rotator cuff tears with and without platelet-rich product supplementation: a meta-analysis and meta-regression. Arthroscopy 31:306–320
35. Zhang Q, Ge H, Zhou J, Cheng B (2013) Are platelet-rich products necessary during the arthroscopic repair of full-thickness rotator cuff tears: a meta-analysis. PLoS ONE 8:e69731

Publisher's Note Springer Nature remains neutral with regard to jurisdictional claims in published maps and institutional affiliations.