

Football player with shoulder pain

Charles J. Gatt, Jr., MD

Chair, Department of Orthopaedic Surgery
Rutgers Robert Wood Johnson Medical School
New Brunswick, NJ



Life In Motion

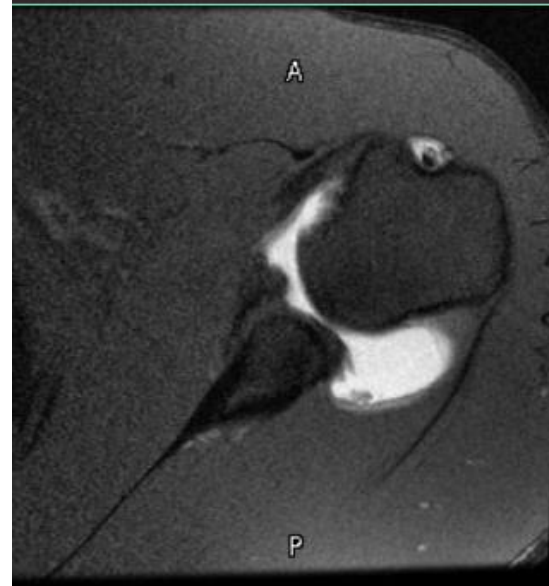
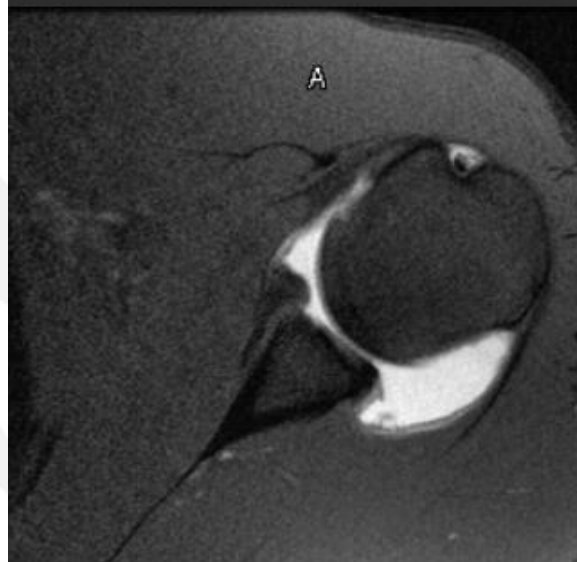
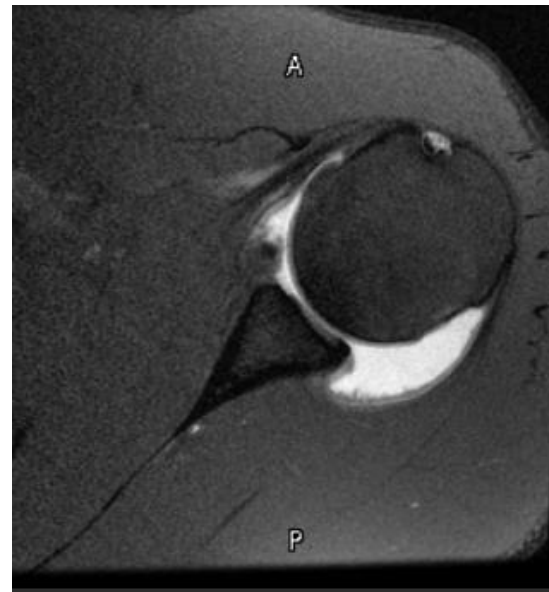
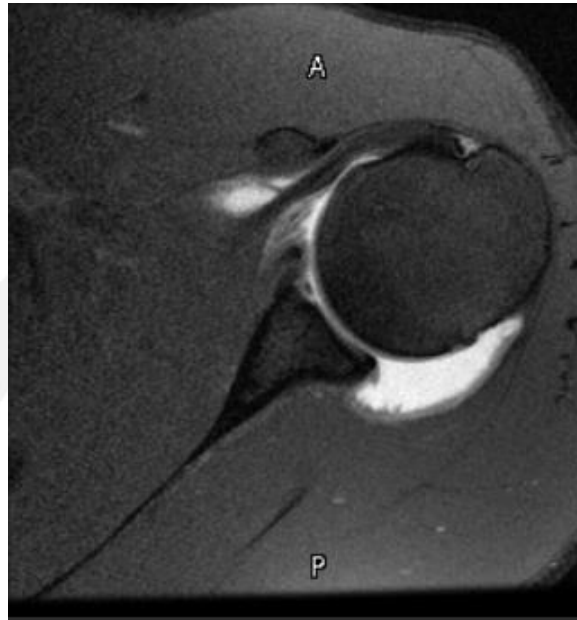
www.UOANJ.com | 1-855-UOA-DOCS

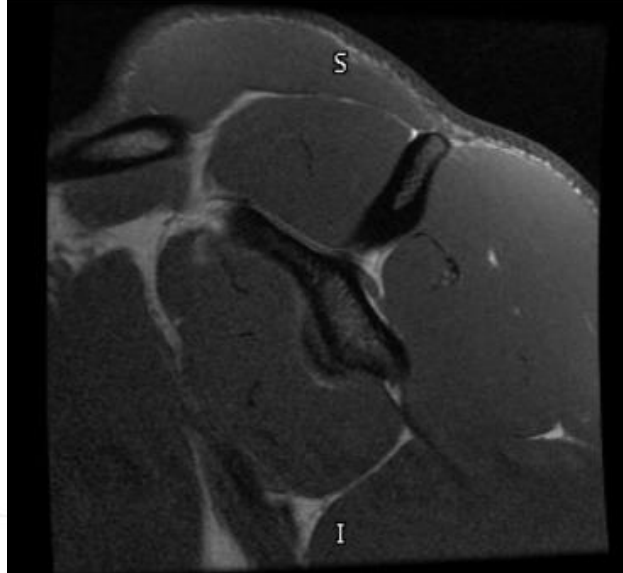
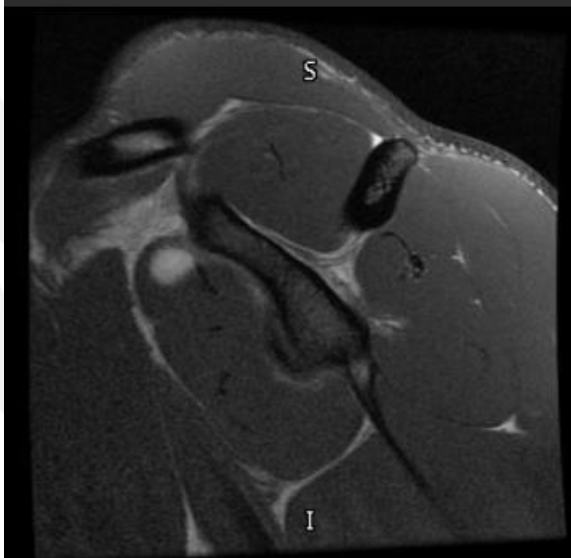
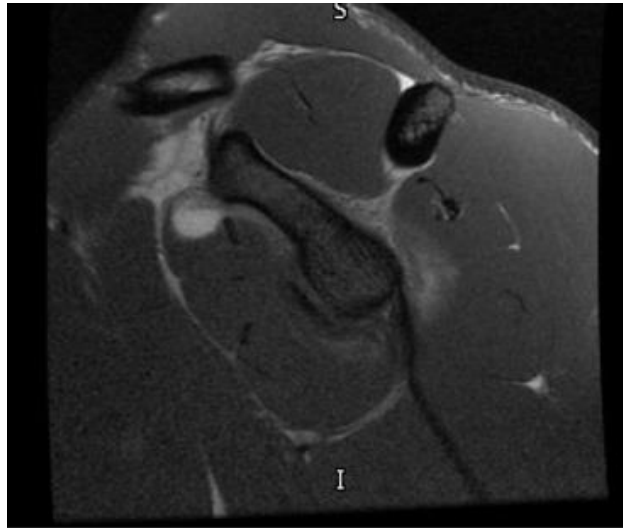
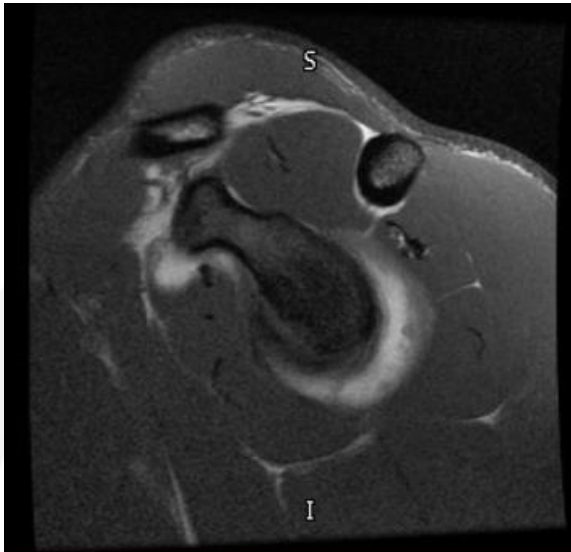
History

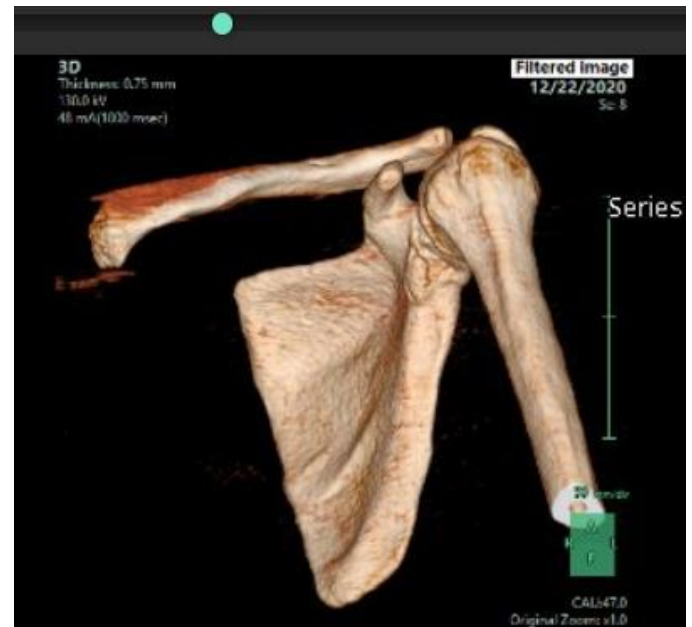
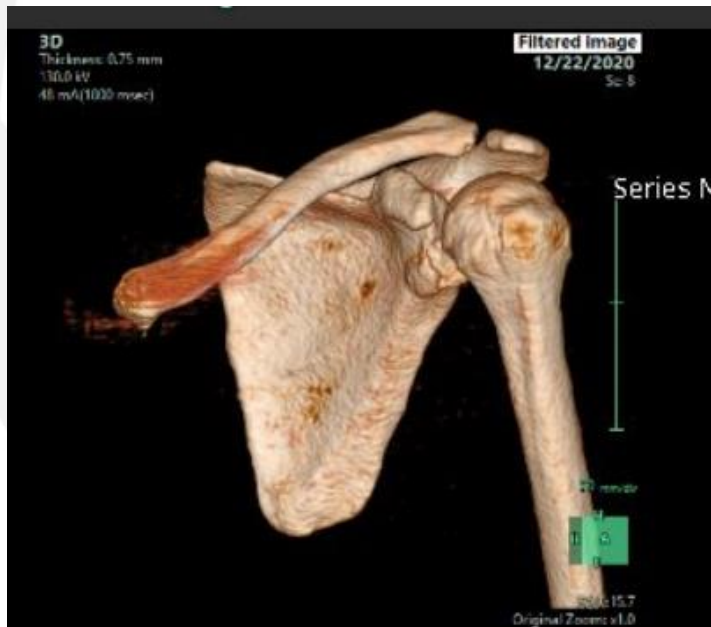
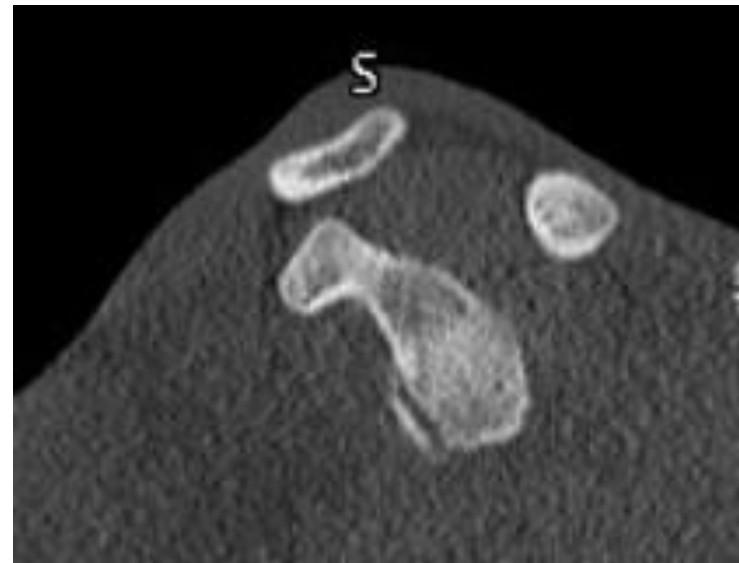
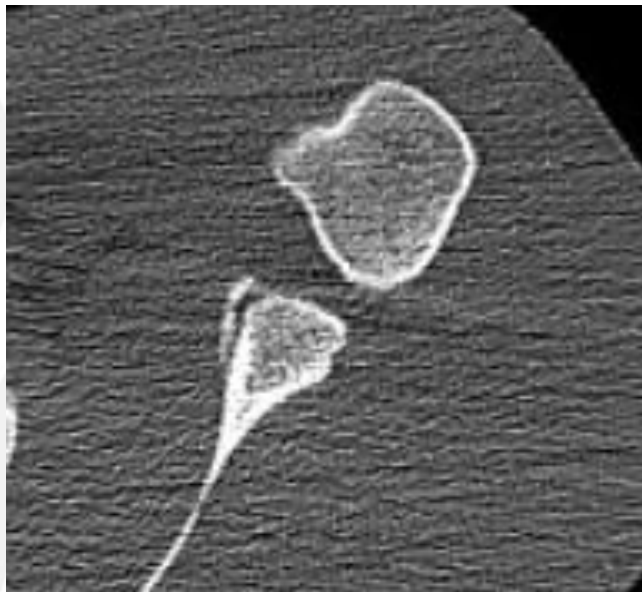
- Collegiate football player – cornerback
- Feeling of shoulder instability
 - No specific event
 - Feeling of pain and weakness

Physical Exam

- Full shoulder ROM
- Good rotator cuff strength
- Guarded with anterior apprehension
- Relief with relocation test







Thank you



Life In Motion

www.UOANJ.com | 1-855-UOA-DOCS